


# Sourdille-Atlantic Ophthalmological Institute

Saint Herblain



## The Institute

At the Institut ophtalmologique Sourdille-Atlantique, Doctor Isabelle Fournier and Anne Albert, her secretary, use OdySight for a close monitoring of their patients suffering from chronic maculopathies between two consultations.

October 2019

The Sourdille-Atlantique Institute started using OdySight\*

77%

Percentage of patients who have downloaded the app after being prescribed it\*

15

Total number of OdySight alerts\*

70

Average age of OdySight patients\*

## Monophthalmia / COVID

OdySight offers additional security to the monophthalmic patient between consultations and allows additional clinical data to be given to the physician, especially in the particular case of COVID 19, with a prolonged limitation of movements.

## Patient case

Mrs. M., who has monophthalmia of the right eye, is being followed by Dr. Fournier. The patient lost her left eye as a result of macular scarring following congenital toxoplasmosis.

- The fundus done in 2018 showed confluent OD drusen, with no evidence of choroidal neovascularization. The examination done at the institute last November showed the appearance of a DEP associated with a thin DSR opposite without an associated choroidal neovascularization.
- The patient initially came once a year, but this was then changed to every month followed by every 3 months, because of her geographical distance.

In particular, this distance justified the prescription of OdySight in November 2019.

- On May 7th, 2020, the practice contacted the patient due to an OdySight alert. An emergency consultation scheduled the following week revealed neovascularization. An injection was made the same day.

\*Data from 06/22/2020

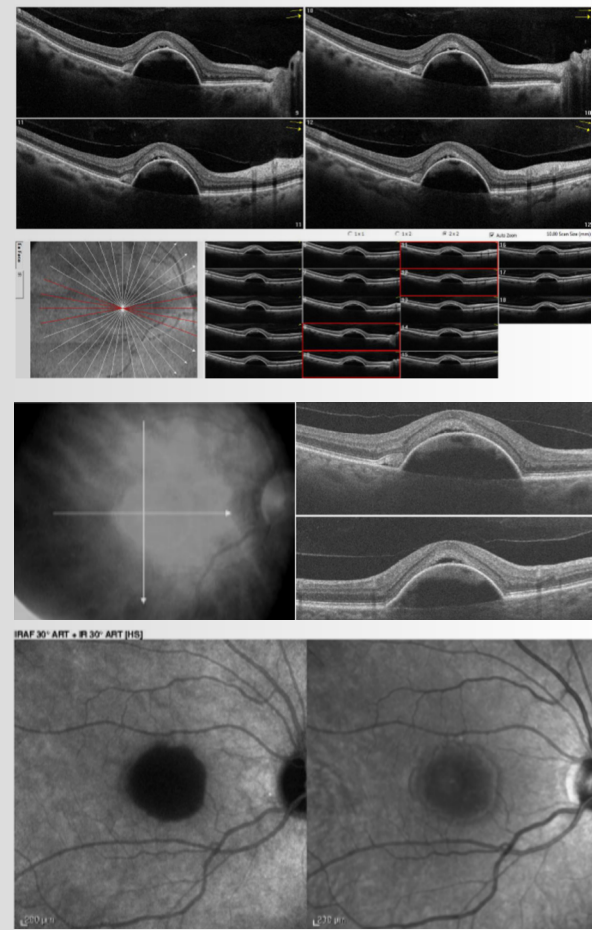
## Using OdySight

At the Sourdille-Atlantique Institute, Dr. Fournier and her secretary work hand in hand for optimal organization:

- The doctor selects the eligible patients during the consultation.
- After the consultation, the patients are redirected to the secretary, who is in charge of delivering the OdySight box.
- The secretary registers patients on the dashboard, according to the information on the patient flyer.
- The secretary keeps an eye on alerts and follow-ups via the dashboard.

02/21/2020

VA	5/10
OCT A	no laces or flows
AF + ICG	large EPDs without identified neovessels



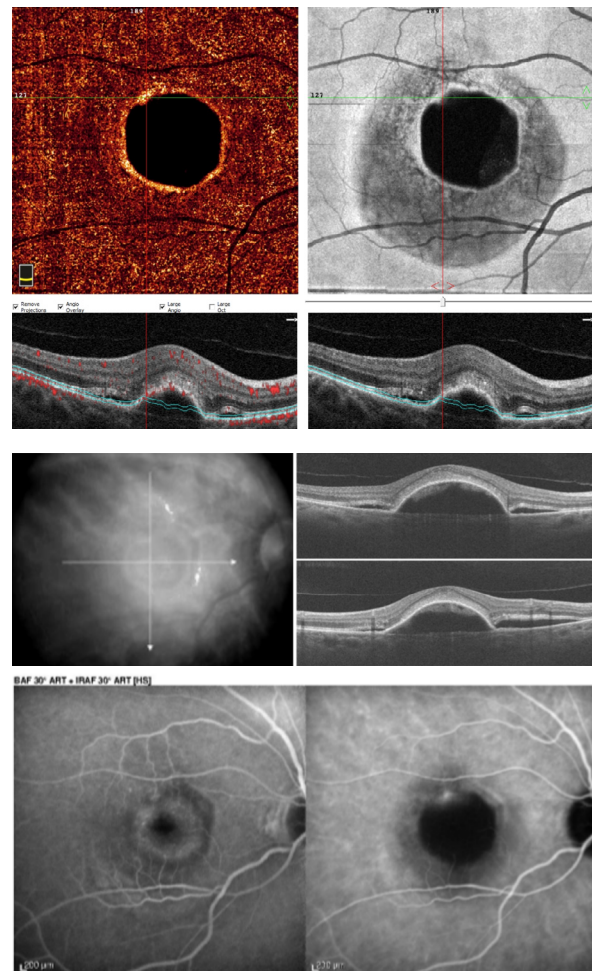
## Two OdySight alerts in April and May

**4/14/2020 Alert:**  
Despite an initial OdySight alert following a slight change in VA likely due to the onset of anatomic change, the patient did not wish to come to an appointment due to the confinement period (Covid-19).

**07/05/2020 Alert:**  
VA drops to 3/10. Consultation scheduled on 05/12/20.

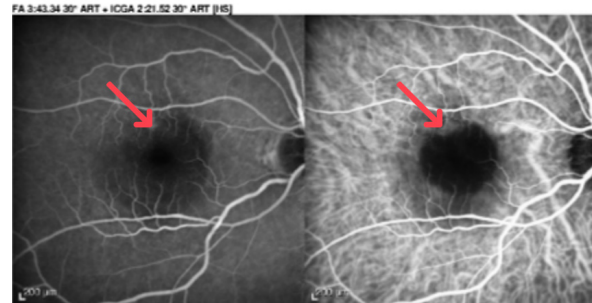
05/12/2020

VA	2/10 weak
EF	Macular OD DEP, no macular hemorrhage
OCT /Angio	OD increase in DSR, appearance of preretinal gray, suspicion of neovessel laceration at the upper border of the OD EPD.



**ANGIO with fluorescein and intracynin:** small hyperfluorescent lesion at the upper border of the EPD.

**ANGIO on indocyanine green:** confirmation of the neovessel at the upper border of the PED.



Intravitreal injection of anti-VEGF the same day. Next IVT scheduled for July 13.

## Patient's OdySight Data

